

Lifting laughter lines

DR KEIREN BONG explains the 3Lift treatment for the nasolabial folds

Wrinkles should merely indicate where smiles have been. This now common saying is especially apt in regard to the nasolabial folds (NLFs)—the two skin creases that run from each side of the nose to the corners of the mouth.

Deepening of these creases is one of the key signs of ageing in the face. As such, softening these lines results in a rejuvenated appearance and a fresher, more youthful look.

Many techniques are available for reducing the prominence of the NLF and as is the case with many areas of aesthetic medicine, this multitude of therapeutic options suggests that we are yet to develop the perfect treatment for these laughter lines, or smile lines. It is true that current treatments each have their own limitations, but with care and practice, it is possible to address deep NLFs and lessen their impact in terms of an aged appearance.

The 3Lift is a new approach demonstrating significant promise for NLF treatment. This technique uses Teosyal's latest range of hyaluronic acid (HA) dermal fillers – resilient hyaluronic acid (RHA) – for rejuvenation and contouring.

The structured approach of the 3Lift focuses on softening the appearance of the NLFs and the treatment protocol is individualised to each patient using Teosyal's RHA3 with lidocaine and, in some cases, RHA4 with lidocaine or PureSense Ultra Deep with lidocaine.

Anatomy of the NLF

A thorough understanding of facial anatomy underpins effective treatment. Treating the NLF is no different.

The NLF courses diagonally in the mid-face from the nasal ala toward the corner of the lip. The crease is accentuated by smiling



because the muscles of facial expression that draw the upper lip in a supero-lateral direction—primarily the zygomaticus major, the zygomaticus minor, and the levator labii superioris—have dermal insertions on the upper lip. Smiling draws the upper lip under the malar fat pad as the pad bulges forward. The lateral nasal artery is in close proximity to the NLF, 2-3mm superior to the alar groove and it is the main vascular supply for the nasal tip and ala.

ADVANTAGES OF 3LIFT

- + Suitable for patients of different morphotypes
- + Natural result
- + Virtually no downtime

Ageing and the NLF

At birth and in early childhood the NLF is absent while the face is at rest. With ageing, the fold becomes visible even when the face is in repose. This change is due to multiple age-related factors including facial volume loss, ptosis of the malar fat pad, atrophy of dermal collagen, and increased skin laxity. The presence of the NLF is also dependent on some baseline tonic activity of the muscles of facial expression, as demonstrated by the disappearance of the fold in patients with paresis of the facial nerve.

Rejuvenation techniques using hyaluronic acid (HA) dermal fillers in the mid-face and NLFs address some of these underlying causes.

Volume restoration

An approach which I've designed

Deepening of the nasolabial folds is one of the key signs of ageing



to reduce prominent NLFs uses volume restoration, either in the NLF alone, or in conjunction with mid-face volume replacement. This approach uses Teosyal's latest range of HA dermal fillers—RHA—to address the dermal atrophy, associated with ageing, that contributes to the development of the NLF. Restoration of contour and volume in the mid-face creates an upward lift, thereby softening the prominence of the NLF.

RHA dermal filler has been the prototypical filler since 2014, with clinicians able to choose the viscosity and degree of cross-linking of the product. In general, and depending on the choice of product, this filler is injected just medial to the NLF but in the mid- to deep-dermal layer. RHA incorporates an anaesthetic agent for patient comfort.

RHA

RHA dermal fillers integrate very well into the ground substance of the dermis and into tissue in general. This is due to the unique molecular structure of RHA dermal

fillers, which results from the use of Teoxane's patented technology during the manufacturing process. The process preserves HA long chains, allowing the formation of a mobile 3D network and giving the HA its viscoelastic capacities. Thanks to these properties, the HA is capable of maintaining tissue architecture, volume and hydration.

In practice, the unique molecular structure of RHA fillers affords superior resilience in withstanding the constant, repetitive stretching and contortions of facial musculatures during facial expressions. The longevity of effects for RHA fillers is typically six to 12 months, or even longer in some cases.

Patient selection

When using RHA filler, consider the quality of the patient's skin, the depth of the fold, the patient's goals regarding degree and longevity of correction and the patient's risk tolerance. Facial assessment involves objective grading of volume loss in the mid-face and NLF, in addition to their structure, symmetry and

proportion. Taking pictures prior to formulating a treatment plan is an effective tool for educating a patient on their facial features and appearance. It also helps you in explaining the rationale for the treatment plan to the patient.

Patients with mild and moderate NLFs are suitable candidates for the 3Lift. Patients presenting with severe NLF, especially with excess skin laxity and hanging skin folds require surgical intervention. The goal of this treatment is to achieve a reduction of NLFs without full effacement.

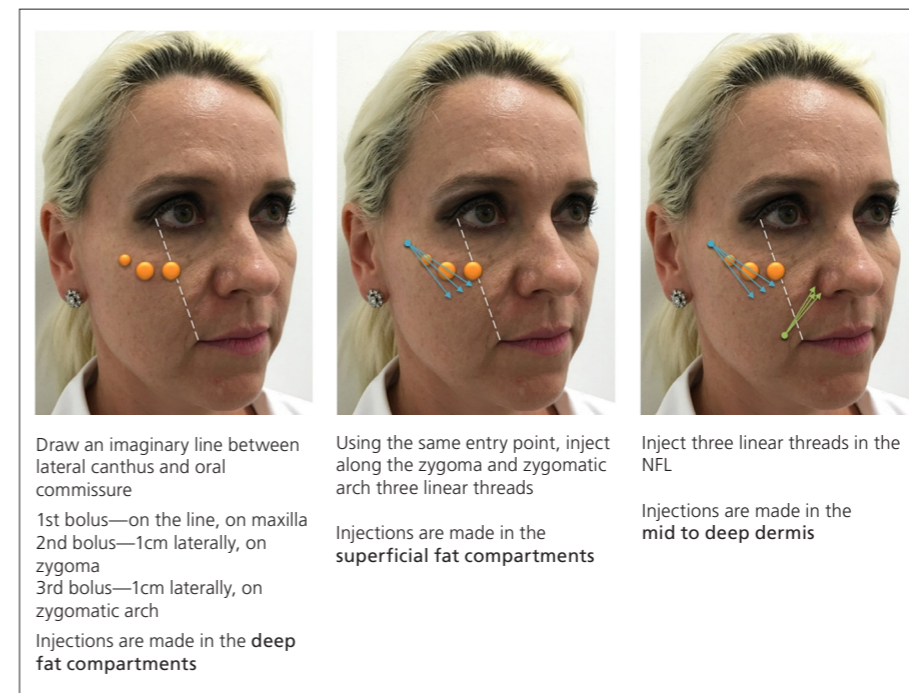
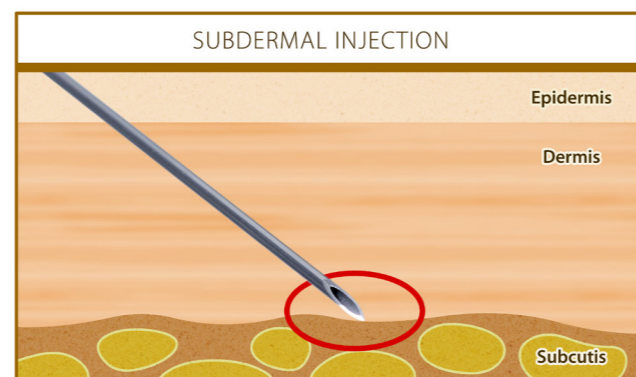
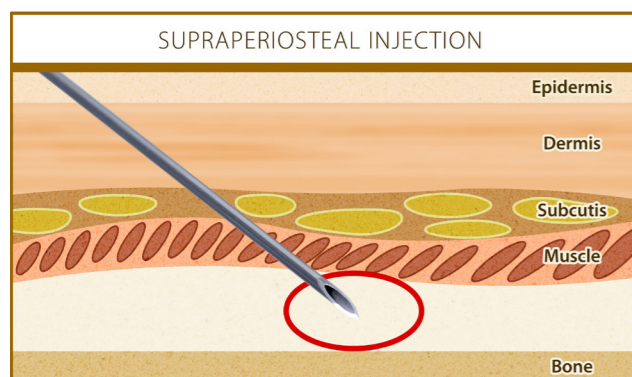
Practical guide

- For mild midface volume loss, mild NFL, use RHA3 in NFL.
- For mild midface volume loss, moderate NFL, use RHA4 in mid-face and RHA3 in NFL.
- For moderate midface volume loss, moderate NFL, use Ultra Deep and RHA4 in midface, and RHA3 in NFL.

RHA4 is injected in superficial fat compartments, Ultra Deep injected in deep fat compartments.

With ageing, the NLF becomes more visible even when the face is in repose

Injection technique



Sequence of injection—three injection sites, three boluses, three linear threads

Injection protocol: Where to inject

The 3Lift has been designed with the use of blunt-tipped micro-cannula.

The NLFs prominence and any concurrent mid-face volume loss will determine the correct injections site for dermal filler. When evaluating potential areas to inject, it is important to remember that contour and volume restoration in one area may lead to improvement in the adjacent area.

For instance, treatment in the maxillary and zygomatic (cheek) areas may improve the appearance of the NLF. This is especially true in patients who have mild to moderate volume loss in the mid-face with minimal or no translocation of mid-face fat pads.

Sequence of injection

Injections in the deep fat compartments create an effective upward

lift in the mid-face. Lateral lift is achieved through the linear threads in the mid-face. More often than not, this sequence of injections alone improves the appearance of the NLF.

Choice of RHA filler

- For deep fat compartments, use the bolus technique with RHA4 or PureSense Ultra.
- For superficial fat compartments, us retrograde linear threading with RHA4.
- For nasolabial folds, use retrograde linear threading with RHA3. Instead of PureSense Ultra Deep, clinicians may use PureSense Ultimate

Volume of product

The volume of product injected in each area will vary from patient to patient, taking account of the following factors: the severity of mid-face volume loss (with or without trans-

location of fat pads); bone structure; the patient's desired outcome and the prominence of the NLF.

Review and subsequent treatments

Teoxane recommends inviting patients for follow-up two weeks after treatment to review results. Visible correction of NLFs using RHA dermal filler typically lasts nine to 12 months after treatment, although longevity of HA dermal fillers is influenced by many factors.

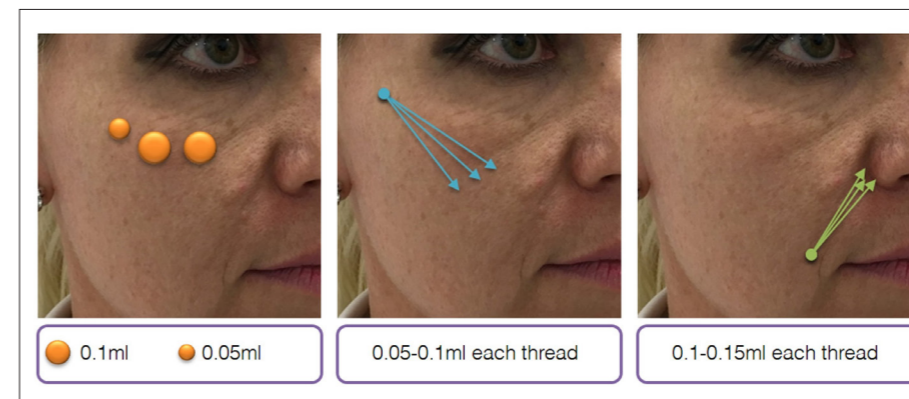
Further consultation at six to 12 months is advisable to establish any need for additional enhancement.

After care instructions

1. Avoid deep tissue massage for two weeks
2. Avoid application of make-up until the following day
3. Minimise touching of injection sites
4. Contact the attending clinician for advice if there are any concerns

References

1. Clemente Anatomy – A Regional Atlas of the Human Body, 4th edition.
2. Gilchrist BA. Cellular and molecular changes in aging skin. *J Geriatr Dermatol* 1994;2:3–6.
3. Stern R, et al. Hyaluronan in skin: aspects of aging and its pharmacologic modulation. *Clin Dermatol*. 2008;26(2):106-22.
4. Anderedd U, et al. More than just a filler – the role of hyaluronan for skin homeostasis. *Exp Dermatol*. 2014;23(5):295-303.
5. Gilbert E. et al. *J Drugs Dermatol*. 2012;11(9):1059-1068.
6. De Maio M. [abstract]. In: Programme and Abstracts. Beauty Through Science. International Aesthetic Symposium Stockholm. 2012.
7. Steven H. Dayan. Facial Dermal Fillers: Selection of Appropriate Products and Techniques. *Aesthetic Surgery Journal* 2008;28:335–347.
8. De Maio M. [abstract]. In: Programme and Abstracts. Beauty Through Science. International Aesthetic Symposium Stockholm. 2012.
9. Monheit GD. & Rohrich RJ. *Dermatol Surg* 2009;35 Suppl 2:1598-1604.



● 0.1ml ● 0.05ml

0.05-0.1ml each thread

0.1-0.15ml each thread