

# A new filler to treat the perioral area


**Wayne D. Carey, Wolfgang Redka-Swoboda, and Giuseppe Sito, discuss treating the perioral area with a filler specifically designed for dynamic aesthetics**

**F**ACIAL AGEING REFLECTS THE combined effects of genetics, time, and environment on the skin, soft tissues, and other structural components of the face<sup>1</sup>. Non-surgical procedures, in particular the use of dermal fillers, have become the mainstay for rejuvenation of the ageing face<sup>2</sup>. Facial rejuvenation has evolved towards the 'full face' approach, not only replacing lost volume in the mid-face, but also correcting specific regions, such as the tear trough and temples, which could not be properly addressed before<sup>3</sup>. With the development of more sophisticated fillers and techniques, and a deeper understanding of facial anatomy, it is now possible to handle a 'full face' approach with fewer side-effects and more natural results than before.

One of the most difficult areas to treat has been the perioral region, as it is the most dynamic. Previous attempts at correcting this area with fillers often resulted in subcutaneous bumps or ridges, or overcorrection because of the rheology of previous hyaluronic acid (HA) fillers. A novel HA filler has been developed (Teoxane Laboratories, Switzerland), which because of a radically different rheology, results in a smooth integration of the filler in the dermis, allowing for ridge-free wrinkle correction in a dynamic area with extremely natural results.

## Perioral lines


Clinically, the perioral area can be divided into two sections; the cutaneous upper and lower lip, and the lower cheeks lateral to the commissures of the lips. Wrinkles in the cutaneous lip areas run the spectrum, from fine almost imperceptible lines, to multiple, deep etchings, commonly referred to as smoker's lines or barcode. The lateral wrinkles of the lower cheeks are often called accordion lines. How evident the appearance of these lines is dependent on the quality of the skin, whether it is atrophic from chronologic ageing, or elastotic from photodamage. A recent study found that these lines were a major concern in 37% of women aged 18 to 75 years old<sup>4</sup>.



**WAYNE D. CAREY, MD, FRCP, CSPQ, FAAD**, Carey Wang Centre for Dermatology and Dermatologic Surgery, Canada



**WOLFGANG REDKA-SWOBODA, MD**, International Consultant for TEOXANE Laboratories, Germany



**GIUSEPPE SITO, PROF, MD**, Aesthetic Medicine Agorà, Italy



The two main presentations of wrinkling in the cutaneous upper and lower lip are either a series of vertical lines radiating from the vermillion border, or a crosshatched pattern where numerous vertical and horizontal lines are present. Accordion lines of the cheeks are usually parallel vertical lines that can extend from the malar prominence to the mandible. The loss of underlying supportive tissues, as well as repeated expressive movements, is often postulated to be the origin of these lines.

## The advent of a new era of dynamic fillers

Different therapies have been utilized in an attempt to correct deep perioral wrinkles. Toxins have been used to address the muscular contraction that may lead to wrinkle formation. However there is a potential side-effect of altering natural lip movement, and the amount of correction is limited<sup>5</sup>. Mesotherapy has minimal to no lifting power or durability and is indicated mainly for the improvement of atrophic, dry skin, not the correction of deep wrinkles<sup>7</sup>. Complete laser

ablation or deep chemical peels were commonly used, and could give excellent results, but required significant downtime for the patient, and had its own side-effects, including permanent hypopigmentation<sup>8</sup>.

The use of HA fillers has become an increasingly popular method to correct perioral lines. However, this

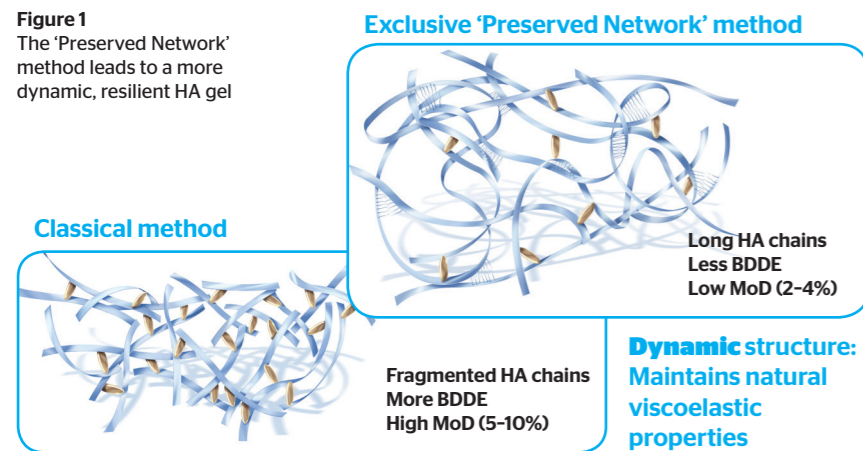
**“One of the most difficult areas to treat has been the perioral region, as it is the most dynamic. Previous attempts at correcting this area with fillers often resulted in subcutaneous bumps or ridges, or over-correction because of the rheology of previous hyaluronic acid (HA) fillers.”**

has been a very challenging area to correct not only due to the continuous movement of this cosmetic subunit, but also, until recently, less than optimal products for this purpose. The continuous motion of the perioral area can make the presence of filler visible due to accumulation of product in areas of decreased resistance to repetitive movement. The more cohesive HA fillers were designed for volumizing depleted fat compartments, and can lead to over-volumization, especially in the cutaneous upper lip. The less cross-linked

fillers have been used for fine lines, but have not been able to correct the deeper barcode or accordion wrinkles very successfully.

Patients are extremely wary of over-volumization of the perioral area, and overwhelmingly desire more >





**Rigid structure:**  
Damages natural viscoelastic properties

▷ natural results. This situation requires a filler that is able to stretch, so as to follow the movements of the injected zone. It should have the characteristics of fluidity, high spreading capacity, and low hygroscopy to clinically achieve a natural appearance. It must also be resilient in order to provide a lasting effect.

To answer those needs, a new HA filler was developed, using a technology called 'Preserved Network' method. The cross-linking process was optimized resulting in less HA chain degradation and a lower amount of BDDE (1,4-Butanediol Diglycidyl Ether). This produced a gel consisting of long HA chains stabilized by natural and mobile interactions, requiring a lower crosslinker rate (Figure 1). This resilient gel has dynamic properties adapted to facial movements. One of the four products developed according to this new technology (TEOSYAL®RHA 1) is especially indicated for fine lines. It can be used for global face rejuvenation, including the neck and décolleté, and is particularly appropriate for the difficult perioral area.

**Injection technique for the perioral area**

Due to its low density, this filler is ideal for perioral lines, which visually disappear or significantly improve when the skin is stretched between fingers. The depth at which this filler is injected is very superficial in the dermal plane. One can visualize the grey of the needle subcutaneously, to confirm the correct depth of placement of product.

The gel is injected with a 30-gauge needle to reduce pain, bruising, and risk of irregularities<sup>9</sup>. It contains lidocaine, to decrease pain during injection. If necessary, topical or local anaesthesia can also be used. It is helpful to mark the wrinkles before using analgesic cream since the subsequent swelling may obscure them, especially fine lines. Alternatively, pinching the skin while injecting or applying a frozen gel pack to the area just prior to injection often is sufficient to control injection discomfort.

Two main injection techniques can be used: A linear

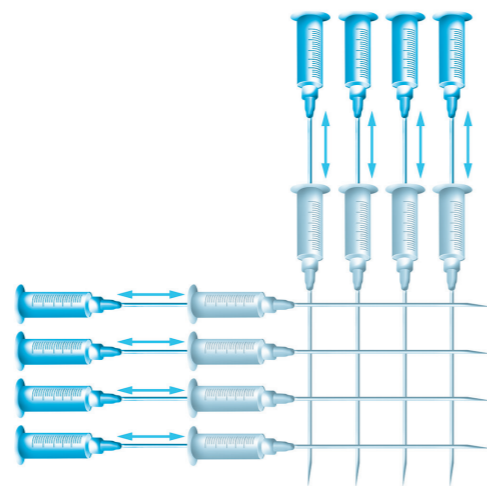
**“ Due to its low density, this filler is ideal for perioral lines, which visually disappear or significantly improve when the skin is stretched between fingers. ”**

antero-retrograde technique for linear wrinkles, and a cross-hatching technique for barcode and accordion lines when numerous fine wrinkles are present. The linear antero-retrograde technique consists of inserting the needle superficially along the length of the wrinkle, regularly depositing the product while moving the needle back and forth multiple times. One can stretch the wrinkle between two fingers while injecting; alternatively one can pinch the wrinkle while injecting, to compress the surrounding blood vessels. Injections should begin from the vermilion border upwards to avoid volumizing the mucosal lip accidentally.



A variation of this technique can be used, especially for deeper wrinkles. A sub-incision is performed initially, running the needle back and forth multiple times before injecting product in an antero-retrograde fashion. The rationale behind this is to create a tunnel to contain the product and limit its spread for better correction.

The cross-hatching technique involves multiple threading injections in a grid pattern, in vertical and horizontal directions. Injections are performed in the sub-epidermal plane, at evenly spaced intervals of 1-2mm. A fan-like pattern of injection can also be used. For extensive lines occurring in elastotic or thick skin, the cross-hatching treatment may be combined with the linear technique.



It should be noted that unlike other HA fillers, the injection of this resilient filler should create a visible ridge of material in order to get satisfactory results. This is reminiscent of the use of early collagen fillers<sup>10</sup>. These ridges will resolve within 24-36 hours. After the procedure, the injected area should be gently massaged with a finger or a cotton swab. There may be transient swelling of the area for 1 to 2 days post-injection. The treatment may be repeated 3 to 4 weeks later, should the need arise. Patients should be informed that it might take a few weeks to see major improvement, to avoid over-

injection. It is highly recommended to schedule a follow-up appointment to ensure best clinical results.

**Preliminary results of a pilot study**

In order to assess the efficacy of TEOSYAL®RHA 1 in reducing barcode lines, a prospective, uncontrolled, pilot study was conducted in Italy by Sito *et al*. In this study, 64 female patients seeking treatment for barcode wrinkles were injected between June and December 2015. All subjects provided written informed consent for the study.

The mean age of the subjects was 48 (36-64) years. Of interest, 67.6% were active smokers, 8.8% were former smokers, and 23.5% had never smoked. The subjects ranged from mild to severe perioral wrinkles, as measured by the Wrinkle Severity Rating Scale<sup>11</sup>. The subjects were not naïve to hyaluronic acid treatments. Subjects were injected with on average 0.8 ml (0.6-1.2ml), with prior application of a 5% lidocaine anaesthetic gel. The primary endpoint was wrinkle appearance at 2 and 6 months post-injection.

Generally, subjects with vertical barcode lines had almost complete improvement of their wrinkles using the antero-retrograde injection technique. Results persisted for at least 6 months. Subjects with numerous cross-hatched lines had significant improvement using a fanning or cross-hatched injection technique that also had a duration of at least 6 months. There were no serious adverse events throughout the study. Modest, transient bruising and erythema were seen in 8 patients, with spontaneous resolution within 48 hours. Specifically, no nodules were observed and there were no adverse events at 2 and 6 months post-injection.

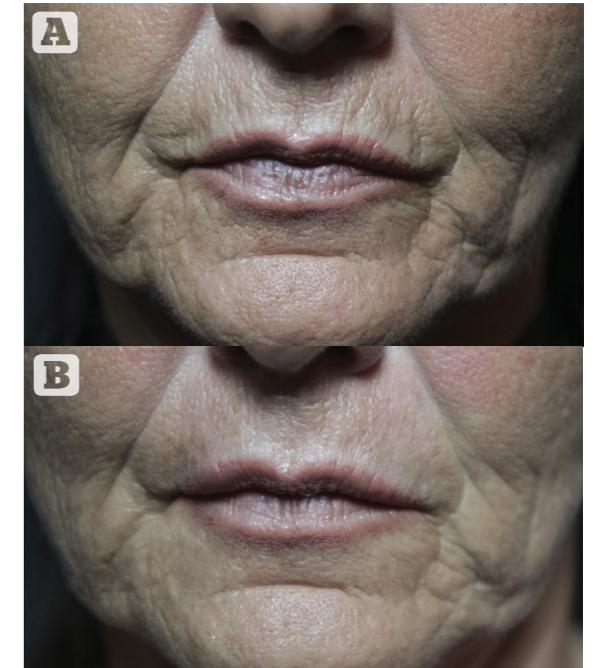**Conclusion**

Treatment of the perioral area with HA fillers has been challenging, but with the development of resilient, long-chain HA fillers such as TEOSYAL®RHA, it is now possible to achieve a natural, and safe correction in a dynamic area. The patented method of preserving long HA chains during the manufacturing process of these hyaluronic acid fillers has produced unique properties that permit their use in mobile areas of the face. The complete integration of the product in the dermis allows the preservation of the natural movements of the face while at the same time producing tissue restoration and rejuvenation effects. TEOSYAL®RHA 1 is a novel and promising product for the treatment of fine lines. Some patients depending on the severity of their perioral lines

Morphotype	Technique	Efficacy			Safety			Patient satisfaction
		DO	M2	M6	DO	M2	M6	
Numerous fine wrinkles	Cross-hatched	Complete correction of wrinkles	Very good correction of the wrinkles	Appearance of some residual wrinkles	Redness mild bruising	No AEs	No AEs	Very good
Linear wrinkles	Antero-retrograde	Complete correction of wrinkles	No evident wrinkles	Reappearance of wrinkles; however, less deep	Redness mild bruising	No AEs	No AEs	Excellent

**Table 1** Efficacy and safety of TEOSYAL®RHA 1 treatment of perioral lines, evaluated immediately after the procedure (DO), and after 2 months (M2) and 6 months (M6)

**Figure 2**  
57 year-old patient (A) before and (B) after 2 ml injections of TEOSYAL®RHA 1 to treat perioral lines. Courtesy of Prof. Giuseppe Sito



may benefit with prior treatment with fractionated laser before the use of HA fillers, to achieve better clinical results with combination therapy. It remains always the clinical judgement of the treating physician the judicious choice and use of the best available therapies for their patients.

► **Acknowledgement** The authors gratefully acknowledge the editorial assistance of Dr. Beatrice Wang.

**References**

- Coleman SR, Grover R. The anatomy of the aging face: volume loss and changes in 3-dimensional topography. *Aesthet Surg J* 2006;26(15): S4-9
- Cotofana S, Fratila AA, Schenck TL, Redka-Swoboda W, Zlinsky I, Pavicic T. The anatomy of the aging face: A review. *Facial Plast Surg* 2016;32(3):253-260
- Pontius AT, Chalet SR, Williams EF 3rd. Midface injectable fillers: have they replaced midface surgery? *Facial Plast Surg Clin North Am*. 2013 May;21(2):229-39
- Carey WD. "The maxi injections of the face." In Alessio Redaelli (Ed.), *Facial Aging - Medical, Surgical and Odontostomatological Solutions for Mid & Inferior Part of the Face*. Florence: Officina Editoriale Oltrano, 2012. Chapter 13, pg. 270
- Florentin A. and Arcane Research. *Aesthetic dermatology, Quantification and potential of the French market: Office and Home Care*. Study held in France in February 2011, which included 4402 women aged 18 to 75
- Kane MA. The functional anatomy of the lower face as it applies to rejuvenation via chemodenervation. *Facial Plast Surg*. 2005 Feb;21(1):55-64
- Baspeyras M, Rouvrais C, Liégard L, Delalleau A, Letallier S, Bacle I, Courrech L, Murat P, Mengeaud V, Schmitt AM. Clinical and biometrical efficacy of a hyaluronic acid-based mesotherapy product: a randomised controlled study. *Arch Dermatol Res*. 2013 Oct; 305(8):673-82
- Alster TS, Lupton JR. Prevention and treatment of side effects and complications of cutaneous laser resurfacing. *Plast Reconstr Surg* 2002;109(1):308-316
- Wollina U. Perioral rejuvenation: restoration of attractiveness in aging females by minimally invasive procedures. *Clin Interv Aging* 2013;8:1149-1155
- Hanke CW, Michalak J. "Soft Tissue Augmentation." *Textbook of Cosmetic Dermatology*, 2nd edition. London: Martin Dunitz, 1998. Chapter 53, pg. 615
- Day DJ, Litterer CM, Swift RW, Gottlieb S. The wrinkle severity rating scale: a validation study. *Am J Clin Dermatol* 2004;5(1):49-52